

THE ROLE OF THE FAMILY DOCTOR IN SCOLIOSIS DETECTION AND MANAGEMENT

A SUMMARY

This information sheet summarises the diagnosis and management principles of adolescent idiopathic scoliosis (AIS). Examination of the spine is recommended for all adolescent girls whenever they visit their family doctor. A full paper on this subject for family doctors is available on this website.

From time to time all public and private schools in Australia will be asked to download the scoliosis brochure from www.scoliosis-australia.org and distribute it to girls in Years 7 and 9. If they, or their parents, think they may have a curve, follow-up with the family doctor is advised. This program is recommended by the Spine Society of Australia. The program is endorsed by the Paediatrics & Child Health Division of the Royal Australasian College of Physicians.

Scoliotic Deformity. AIS develops about 10 years of age in a previously normal spine. It deforms in the coronal and sagittal planes together with rotation in its long axis. The vertebral body rotates to the convex side and the spinous processes to the concave. The ribs follow the vertebrae rotating backwards and upwards on the convex side and forward to a lesser degree on the concave.

Curve patterns. The right thoracic curve is the most common pattern followed by the left lumbar curve.

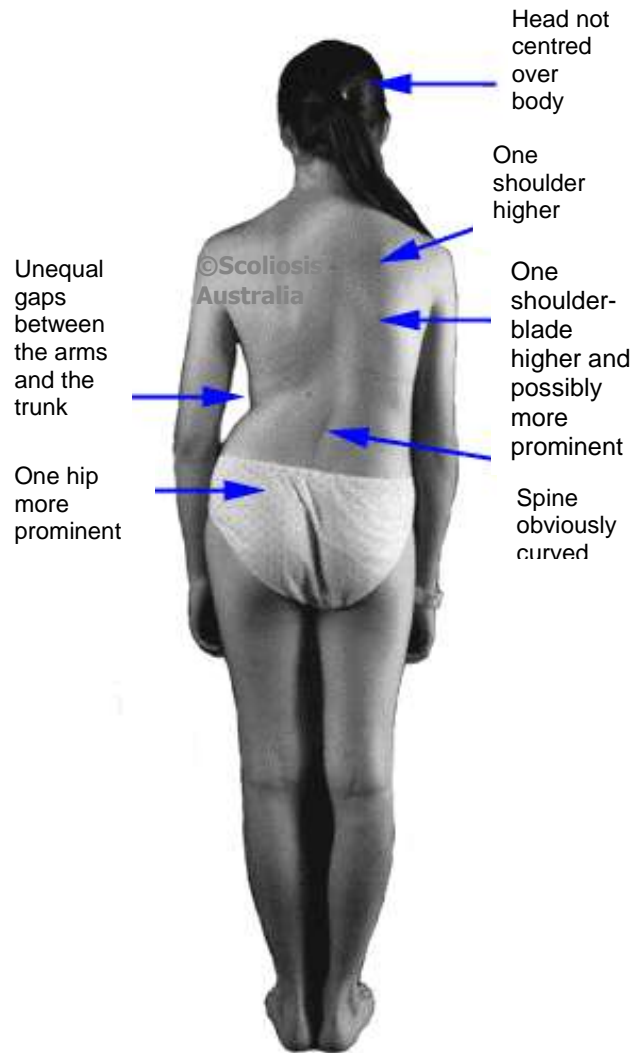
Prevalence. 2%-3% for curves 10° or more; 0.1% for curves >40°.

Sex incidence. The male-female ratio for curves warranting treatment is 1:10.

Diagnosis. This is best made when the trunk is viewed from behind. In a right (R) thoracic curve the R shoulder is elevated and the left (L) arm may appear longer. The R scapula moves upwards and laterally with a prominent medial edge. Because of trunk rotation, the L breast may be more prominent than the R. Flank creases may be asymmetrical in an overweight girl. The gaps between the dependent arms and the trunk are unequal. The L iliac crest (hip) is more prominent than the R. The latter may be the presenting signs in the thoracolumbar and lumbar curves.

The forward-bend test (FBT). This diagnostic physical sign is based on fixed (structural) vertebral column rotation. The subject bends maximally forward with outstretched arms, palms facing each other, pointed towards the great toes with the feet together. This brings the rib prominence or lumbar muscles into silhouette. A significant curve is likely if the difference between the heights of the two sides is >1cm.

WHAT ARE THE OUTWARD SIGNS OF SCOLIOSIS?



HOW DO YOU DETECT SCOLIOSIS?

SIMPLY LOOK FOR IT! IT ONLY TAKES 30 SECONDS

Torso asymmetry. This is the most common reason for a false positive FBT. It is due to asymmetrical growth/development of the two sides of the body and is present in about 40% of normal girls. Here, in the FBT, the difference between the heights of the two sides is <1cm. The other signs of scoliosis are absent. If you are having difficulty deciding whether or not a girl has a curve, then almost certainly she does not. Such asymmetry is of no clinical significance.

Symptoms. In the early stages, AIS causes no symptoms. A painful scoliosis is an indication for investigation for underlying pathology such as tumour.

Curve measurement (The Cobb Angle). This must be done accurately on an erect PA film (diagram). The minimal angle for diagnosis is 10° with vertebral rotation.

Scoliosis of other aetiologies. AIS is a diagnosis by exclusion. A full physical examination is required. Curvature may be associated with neuromuscular disease, connective tissue disorder and congenital vertebral abnormalities. Specialist referral is recommended for these conditions. A true or apparent limb shortening may produce a lumbar tilt but not scoliosis. This is because there is no vertebral rotation. A short leg "scoliosis" disappears on sitting and in the FBT.

THE FORWARD BEND TEST 30 SECONDS WELL SPENT FOR AN ADOLESCENT GIRL AND HER FAMILY DOCTOR

Management. This is based on the age at presentation and the degree of curvature. The risk for progression is established (table) and this most likely occurs in the growth spurt (11-13 yrs). Early breast development marks spurt onset.

- For curves <20°: Observation only through the growth phase on a six-monthly basis. Specialist referral not required.
- For curves 20°-40°: Bracing may be required if there is documented progression >5°. One third of curves in this range do not progress.

There is no scientific evidence that physical therapy (exercise programs) and spinal manipulation (chiropractic adjustments) will either correct a scoliosis or halt its progression.

No restrictions are placed on any activity - this includes sport. Detection of a curve is an indication for examination of siblings. AIS may be inherited on an autosomal basis.

Minor curves (<20°) are common but only 3 adolescent girls per 1000 have a curve which requires active treatment, either by bracing or surgery.

RISK OF PROGRESSION IN AIS

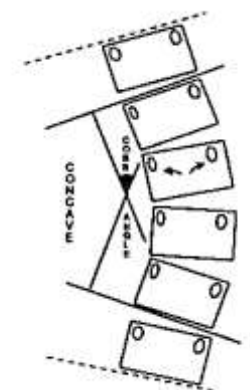
Degree of curve Cobb angle	Age 10-12	Age 13-1	Age over 16
<20°	25%	10%	0%
20°-30°	60%	40%	10%
30°-60°	90%	70%	30%
>60°	100%	90%	70%

Data generated by the Scoliosis Research Society, Chicago, Illinois, USA



A positive forward bend test in a girl with a thoracolumbar curve. Thoracic curves are best detected with the examiner standing directly behind the subject and in front for thoracolumbar and lumbar curves.

MEASUREMENT OF THE COBB ANGLE ON AN ERECT PA X-RAY



The angle is measured at the intersection of perpendiculars drawn to lines parallel to the upper and lower surfaces of the vertebrae which tilt towards the concavity (solid lines). Measurement using the vertebrae above and below (dotted lines) would give a false value as these surfaces do not tilt toward the concavity. When a vertebra rotates the pedicle shadows become asymmetrical (arrows).

©Scoliosis Australia
is a project of



The National Self-Detection
Program for Scoliosis is supported by



www.scoliosis-australia.org